

Clinical Practice Guidelines for Hepatic Arterial Infusion Chemotherapy with a Port System Proposed by the Japanese Society of Interventional Radiology and Japanese Society of Implantable Port Assisted Treatment

Kazuomi Ueshima^a Atsushi Komemushi^b Takeshi Aramaki^c Hideki Iwamoto^d
Shuntaro Obi^e Yozo Sato^{f,g} Toshihiro Tanaka^h Kiyoshi Matsueda^f
Michihisa Moriguchiⁱ Hiroya Saito^j Miyuki Sone^l Takuji Yamagami^k
Yoshitaka Inaba^g Masatoshi Kudo^a Yasuaki Arai^l

^aDepartment of Gastroenterology and Hepatology, Kindai University Faculty of Medicine, Osaka, Japan;

^bDepartment of Radiology, Kansai Medical University Medical Center, Osaka, Japan; ^cDivision of Interventional

Radiology, Shizuoka Cancer Center, Shizuoka, Japan; ^dDivision of Gastroenterology/Iwamoto Internal Medicine

Clinic, Department of Medicine, Kurume University School of Medicine, Fukuoka, Japan; ^eDepartment of Internal

Medicine, Teikyo University Chiba General Medical Center, Chiba, Japan; ^fDepartment of Diagnostic Ultrasound

& Interventional Radiology, Cancer Institute Hospital of Japanese Foundation for Cancer Research, Tokyo, Japan;

^gDepartment of Diagnostic and Interventional Radiology, Aichi Cancer Center Hospital, Aichi, Japan; ^hDepartment

of Radiology/IVR Center, Nara Medical University, Nara, Japan; ⁱDepartment of Molecular Gastroenterology

and Hepatology, Kyoto Prefectural University of Medicine Graduate School of Medical Science, Kyoto, Japan;

^jImaging and IVR Center, Sapporo Higashi Tokushukai Hospital, Hokkaido, Japan; ^kDepartment of Diagnostic and

Interventional Radiology, Kochi Medical School, Kochi, Japan; ^lDepartment of Diagnostic Radiology, National Cancer

Center Hospital, Tokyo, Japan

Keywords

Hepatic arterial infusion chemotherapy · Hepatic arterial infusion chemotherapy with a port system · Liver cancer · Hepatocellular carcinoma · Liver metastases

Abstract

Hepatocellular carcinoma is one of the leading causes of cancer-related death both in Japan and globally. In the advanced stage, hepatic arterial infusion chemotherapy (HAIC) is one of the most commonly used treatment options for liver cancer in Japan, and implantation of a catheter system (called a port system) in the body is a treatment method that has evolved mainly in Japan. The Guideline Committee of

the Japanese Society of Interventional Radiology and the Japanese Society of Implantable Port Assisted Treatment jointly published clinical practice guidelines for HAIC with a port system to ensure its appropriate and safe performance in Japanese in 2018. We have written an updated English version of the guidelines with the aim of making this treatment widely known to experts globally. In this article, the evidence, method, indication, treatment regimen, and maintenance of the system are summarized.

© 2022 The Author(s).

Published by S. Karger AG, Basel

Kazuomi Ueshima and Atsushi Komemushi contributed equally to this work.

Introduction

Hepatic arterial infusion chemotherapy (HAIC) has been performed to treat liver cancer in many countries; however, it is less frequently performed in Western countries than in Asian countries because of the lack of evidence of a survival benefit. HAIC has been adapted to the treatment algorithm in the Japan Society of Hepatology (JSH) practice guidelines for hepatocellular carcinoma (HCC) as well as Taiwanese guidelines; conversely, this method has not been included in practice guidelines in other countries, such as the American Association for the Study of Liver Diseases (AASLD), European Association for the Study of the Liver (EASL), and Asian Pacific Association for the Study of the Liver (APASL) guidelines [1–5]. Also, it has not been included in practice guidelines from the international society for medical oncology, such as the American Society of Clinical Oncology (ASCO) or European Society for Medical Oncology (ESMO) [6, 7]. In Japan, HAIC is considered an effective treatment option for liver tumors, and it is widely performed. In addition, the regimen of HAIC varies by country; therefore, there is no uniform regimen worldwide. Meanwhile, the literature describing the current proper HAIC methodologies is insufficient. This clinical practice guideline specific to HAIC with a port system was established by the Japanese Society of Interventional Radiology (JSIR) and the Japanese Society of Implantable Port Assisted Treatment (JSIPAT) in collaboration with JSH to provide a consensus statement on HAIC. The purposes of this document were to provide a deep understanding of HAIC with a port system and to ensure the standardization and safety of HAIC worldwide.

Target Audience

This guideline was established to ensure the appropriate and safe performance of HAIC with a port system by medical professionals who treat liver cancer.

Method of Guideline Development

We first searched the literature on HAIC with a port system. On October 24, 2020, PubMed was searched using the terms “intra-arterial chemotherapy” and “hepatic arterial infusion.” No publication date was specified in the search, and 653 references were retrieved.

The committee members performed a manual search of the abstracts identified in PubMed as a primary screening in reference to the JSH “Clinical Practice Guidelines for Hepatocellular Carcinoma 2017,” and 94 relevant papers were identified. Another search of studies written in Japanese identified seven additional references. In total, 101 references were therefore reviewed in the development of these guidelines.

The strengths of the level of evidence and recommendations were stipulated according to the Grading of Recommendations Assessment, Development, and Evaluation system recommended by “Minds Handbook for Clinical Practice Guideline Development 2014” to fill the gap between evidence and clinical practice as follows [8, 9]: Strength of recommendation: strong, weak. Summary of the level of evidence: A, strong; B, moderate; C, weak; D, very weak. For clinical questions that lacked studies with a strong level of evidence and that were difficult to evaluate objectively, the recommendations were based on the consensus of the committee members.

Key Clinical Questions

Key questions frequently faced in clinical settings were proposed by the committee members, who are professionally engaged in the treatment of HAIC. The key clinical questions identified were as follows:

1. What is HAIC with a port system?
2. What are the indications for HAIC with a port system in HCC?
3. What regimens should be used in HAIC with a port system for HCC?
4. What are the therapeutic outcomes of HAIC with a port system for HCC?
5. What therapies can be combined with HAIC with a port system for HCC?
6. What are the indications of HAIC with a port system for liver metastases?
7. What regimens should be used in HAIC with a port system for metastatic liver cancer?
8. What are the therapeutic outcomes of HAIC with a port system for liver metastases?
9. What are the complications and treatments of HAIC with a port system?
10. What is the appropriate method for implanting the catheter and port system?
11. How should an implanted catheter and port system be managed after placement?
12. For which clinical conditions should HAIC with a port system be suspended or discontinued?

1. What Is HAIC with a Port System?

Statements

HAIC with a port system is a treatment method for liver neoplasms, with the port system enabling the direct injection of chemotherapeutic agents into target lesions in the liver. The difference between HAIC and a one-shot intra-arterial injection is that continuous administration of time-dependent cytotoxic antitumor agents such as 5-fluorouracil can be performed easily and safely.

Commentary

The port system was developed to allow patients to receive repeated injections of chemotherapeutic agents safely and easily without compromising their quality of life. This port system is called a “reservoir” or “port.”

The system consists of a catheter and a port. Generally, the port is a device defined according to the following conditions: (1) it is connected to a catheter placed in a vessel, and the catheter system is suitable for placement in the body over a long period; (2) it has an internal chamber that directly communicates with the internal lumen of the catheter, and after subcutaneous placement, it enables repeated puncture to inject a drug or drain body fluid via percutaneous puncture; and (3) it does not have a pump function for continuous injection or drainage [10]. The port was developed in the United States and Japan and was first reported in 1982 in both countries [11–13].

HAIC with a port system uses the aforementioned features to administer treatments for liver neoplasms, with the port system enabling the direct injection of chemotherapeutic agents into the target lesions in the liver through the hepatic artery. The device used in HAIC with a port system was first reported by Arai et al. [11].

Another type of port system is System-I [14], which enables a microcatheter to be repeatedly inserted into the artery via percutaneous puncture. The microcatheter inserted via System-I is guided to the feeding artery of the target lesion and is used to inject drugs or embolic agents.

HAIC without a port system has also been described. It is used when administering concentration-dependent anticancer drugs such as cisplatin and epirubicin, and it is less invasive to patients. However, if repeated doses are required, a port system may be used in consideration of patient convenience.

HAIC has the advantage of cost-effectiveness. For example, regarding HCC treatment in Japan as of December 2021, the cost of low-dose 5-fluorouracil and cisplatin (FP) therapy is JPY 53,488 (USD 465 converted at 115

yen per USD) per course in patients with a body surface area of 1.75 m² (170 cm, 65 kg). Conversely, sorafenib, lenvatinib, and atezolizumab plus bevacizumab carry costs of JPY 533,568 (USD 4639), JPY 338,495 (USD 2943), and JPY 898,235 (USD 7811), respectively. Therefore, HAIC is extremely inexpensive compared with other systemic chemotherapies (online suppl. Table S1; see www.karger.com/doi/10.1159/000524893 for all online suppl. material).

2. What Are the Indications for HAIC with a Port System in HCC?

Recommendations

HAIC with a port system is generally indicated for patients with multiple intrahepatic lesions or vascular invasion. However, HAIC may also be an option even in patients with extrahepatic metastasis when intrahepatic lesions or vascular invasion determine the patient's prognosis. However, HAIC with a port system may be the better treatment option for patients with treatment-naïve major vascular invasion because of its greater local control of vascular invasion. In addition, HAIC with a port system is the most suitable treatment option for patients with poor liver function, such as Child–Pugh class B not indicated for systemic chemotherapy (weak recommendation, level of evidence C; Fig. 1).

Commentary

HAIC with a port system is generally indicated for patients with multiple intrahepatic lesions or vascular invasion. However, HAIC may also be an option in patients with extrahepatic metastasis when intrahepatic lesions or vascular invasion influence the patient's prognosis. Thus, in such situations when patients have Child–Pugh class A liver function, systemic chemotherapy such as atezolizumab plus bevacizumab [15], sorafenib [16], or lenvatinib [17] is ordinarily the first treatment choice [18]. In that sense, HAIC is indicated for patients who are refractory to standard systemic chemotherapy. However, HAIC with a port system may be the better candidate treatment option for patients with treatment-naïve major vascular invasion because of its greater local control of vascular invasion. In addition, HAIC with a port system is the most suitable treatment option for patients with poor liver function, such as Child–Pugh class B not indicated for systemic chemotherapy. Next, we will describe the tumor situations in which HAIC is indicated and characterize them by





Indication of Hepatic arterial infusion chemotherapy with a port system for hepatocellular carcinoma			
Stage		Child-Pugh A	Child-Pugh B (Score 7–8)
Intermediate stage		× Not suitable (Molecular targeted agents preferred)	<input type="checkbox"/> Good candidate
Advanced stage with macrovascular invasion			
Naïve case		○ Recommended	<input type="checkbox"/> Good candidate
TACE failure/refractoriness case		× Not suitable (Molecular targeted agents preferred)	<input type="checkbox"/> Good candidate
Advanced stage with extrahepatic spread (If intrahepatic lesions or vascular invasion influences the patient's prognosis)		<input type="checkbox"/> Good candidate	<input type="checkbox"/> Good candidate

Fig. 1. Indications of HAIC with a port system for HCC.

tumor factors, liver function, clinical characteristics, and other factors.

1. Tumor size/tumor number and distribution

A maximum tumor size of ≥ 5 cm is reported to be associated with more rapid progression and poorer prognosis [19], although other studies reported no difference in progression-free survival (PFS) compared with the findings in patients with tumor sizes of ≥ 10 cm [20–22]. However, most of the studies that found no difference in PFS did not examine the outcomes of HAIC alone. A large tumor size may lead to poor drug distribution and insufficient local drug concentrations inside the tumor. Therefore, careful consideration should be given to the use of HAIC in patients with large tumors. It was reported that the objective response rate (ORR) and overall survival (OS) were lower in bilobar multiple HCC than in hemilobar HCC [20]; however, there is insufficient evidence to comment on differences in the efficacy of HAIC according to the tumor distribution.

2. Tumor volume and tumor occupation rate

Patients with a tumor volume ≥ 400 mm³ were found to have inferior OS (hazard ratio [HR] = 2.520, 95% confidence interval [CI] = 1.252–5.072, $p = 0.01$), but PFS and ORR data were not reported [23]. When tumors occupied $\geq 50\%$ of the liver, HAIC was associated with poor ORR, which affected OS [21]. In univariate analysis, an occupation rate $\geq 50\%$ affected tumor progression and the ORR of HAIC, although multivariate analysis did not identify any significantly associated factors [19, 24]. Thus, it is difficult to reach any firm conclusions regarding the effects

of the tumor occupation rate on the efficacy of, or indications for, HAIC.

3. Macroscopic growth pattern

No significant correlation was reported between the macroscopic growth pattern and the therapeutic effect of HAIC with a port system using lipiodol in combination with unspecified cytotoxic antitumor agents [20]. Furthermore, univariate analysis of HAIC for nodular and non-nodular lesion types found a significant effect on OS, although no difference was observed in multivariate analysis [19]. The authors did not discuss any relationship with a direct antitumor effect.

4. Patients with portal vein invasion

A phase III randomized controlled trial (RCT) was conducted in Japan to verify the additional effect of HAIC with a port system using low-dose FP (SILIUS trial). The results did not meet the primary endpoint, but a sub-analysis suggested that HAIC with a port system had an additional effect in patients with HCC and main portal invasion [25]. Another phase III study from China reported that combining sorafenib with HAIC using oxaliplatin + 5-fluorouracil + leucovorin improved OS versus sorafenib alone in patients with portal vein invasion [22]. Furthermore, retrospective studies recorded positive outcomes for HAIC in comparison with sorafenib, suggesting that HAIC may have provided a survival benefit in patients with HCC and portal vein invasion [19, 26, 27].

The pathological condition of portal vein invasion can be classified into two patterns: portal vein invasion caused

by the ineffectiveness of transcatheter arterial chemoembolization (TACE) and treatment-naïve portal vein invasion. It has been reported that the OS in patients with portal vein invasion caused by TACE is much shorter than that in patients with treatment-naïve portal vein invasion (7 months vs. 13.4 months), and the ORR is also lower in patients with portal vein invasion caused by TACE (18% vs. 39%). This means that HAIC with an implanted port system is suitable for cases of treatment-naïve portal invasion.

However, a number of new regimens for HCC have recently been approved. Lenvatinib was linked to a higher ORR than sorafenib as well as non-inferior OS [17]. A phase III trial of lenvatinib excluded patients with main portal invasion and an intrahepatic tumor occupation rate $\geq 50\%$, meaning that its efficacy and safety have not been verified for these tumor conditions. However, in clinical settings, lenvatinib is widely used for advanced HCC with portal vein invasion. Atezolizumab plus bevacizumab produced a survival benefit compared with sorafenib alone in the IMbrave150 trial [15]. In this study, approximately 40% of patients had major portal invasion, and atezolizumab plus bevacizumab is currently the first treatment option for patients with portal vein invasion. Because the number of available treatment options has increased, it is necessary to thoroughly consider whether HAIC or systemic therapy should be used in patients with Child–Pugh class A HCC and portal vein invasion, for which molecular targeted agents are indicated, although HAIC with a port system is indicated for patients with Child–Pugh class B HCC and portal vein invasion.

5. Patients with hepatic vein invasion

In cases of HCC with hepatic vein invasion, an intrahepatic lesion response to HAIC with a port system in combination with radiation therapy was found to improve prognosis [21]. However, there is no consensus on the usefulness of HAIC in HCC with hepatic vein invasion.

6. HCC refractory to TACE

The outcomes of TACE-refractory patients following propensity score matching were significantly better with sorafenib treatment than with HAIC with a port system [28]. In another report, a TACE-refractory status was identified as a contributing factor to OS (HR = 1.6, 95% CI = 1.09–2.4, $p = 0.04$) [29]. These results indicate that HAIC may not be suitable for TACE-refractory patients.

7. Patients with poor liver function

HAIC with a port system can be safely performed with modest efficacy in patients with Child–Pugh B liver func-

tion, but the ORR and OS are insufficient in patients with a Child–Pugh score of 9 [24, 30]. Furthermore, HAIC with a port system will occasionally improve liver function from Child–Pugh B to Child–Pugh A when a response occurs [30].

8. Progression after systemic chemotherapy

With the advancement of systemic chemotherapy for HCC in recent years, multiple systemic chemotherapeutic regimens have become available [15–17, 31–33]. Therefore, in cases of first-line therapy failure, if the patient still has Child–Pugh A liver function, another chemotherapeutic agent is indicated as a second-line therapy [18].

However, if liver function deteriorates to Child–Pugh B, systemic chemotherapy is not applicable. In such a case, HAIC may be the better treatment candidate in patients with Child–Pugh B. For example, relatively positive outcomes have been reported for HAIC with a port system after sorafenib, with an ORR of 29.6% and an OS of 7.6 months [34]. HAIC may even be tolerated in patients with Child–Pugh B liver function as a later-line therapy. However, no therapeutic effects of HAIC have been reported except after sorafenib therapy.

9. Patients with extrahepatic lesions

Extrahepatic lesions were not identified as an independent prognostic factor for OS following HAIC [7], and the presence or absence of extrahepatic lesions did not impact the prognosis in patients with portal vein invasion (median OS: 8 months for extrahepatic spread [EHS] [–] vs. 5 months for EHS [+], $p = 0.201$) [11], suggesting that HAIC affects survival, even in the presence of extrahepatic lesions. However, HAIC is generally ineffective against extrahepatic lesions, the presence of which was identified as a significant factor related to disease progression (HR = 1.748, 95% CI = 1.153–2.646, $p = 0.008$) and shorter OS (EHS [–] vs. [+]; HR = 0.543, 95% CI = 0.356–0.829, $p = 0.0046$) [20]. These results indicate that the use of HAIC should be given careful consideration in patients with extrahepatic lesions.

10. Etiology of liver disease

Several studies reported that the effects of HAIC with a port system were relatively better in patients with hepatitis C-related HCC (hepatitis C [+] *vs.* hepatitis C [–]: odds ratio = 16.886, $p = 0.010$; hepatitis C [+] *vs.* hepatitis C [–]: odds ratio = 2.436, $p = 0.005$) [9, 12]; however, other studies did not observe a significant difference, which indicates the lack of a consensus.

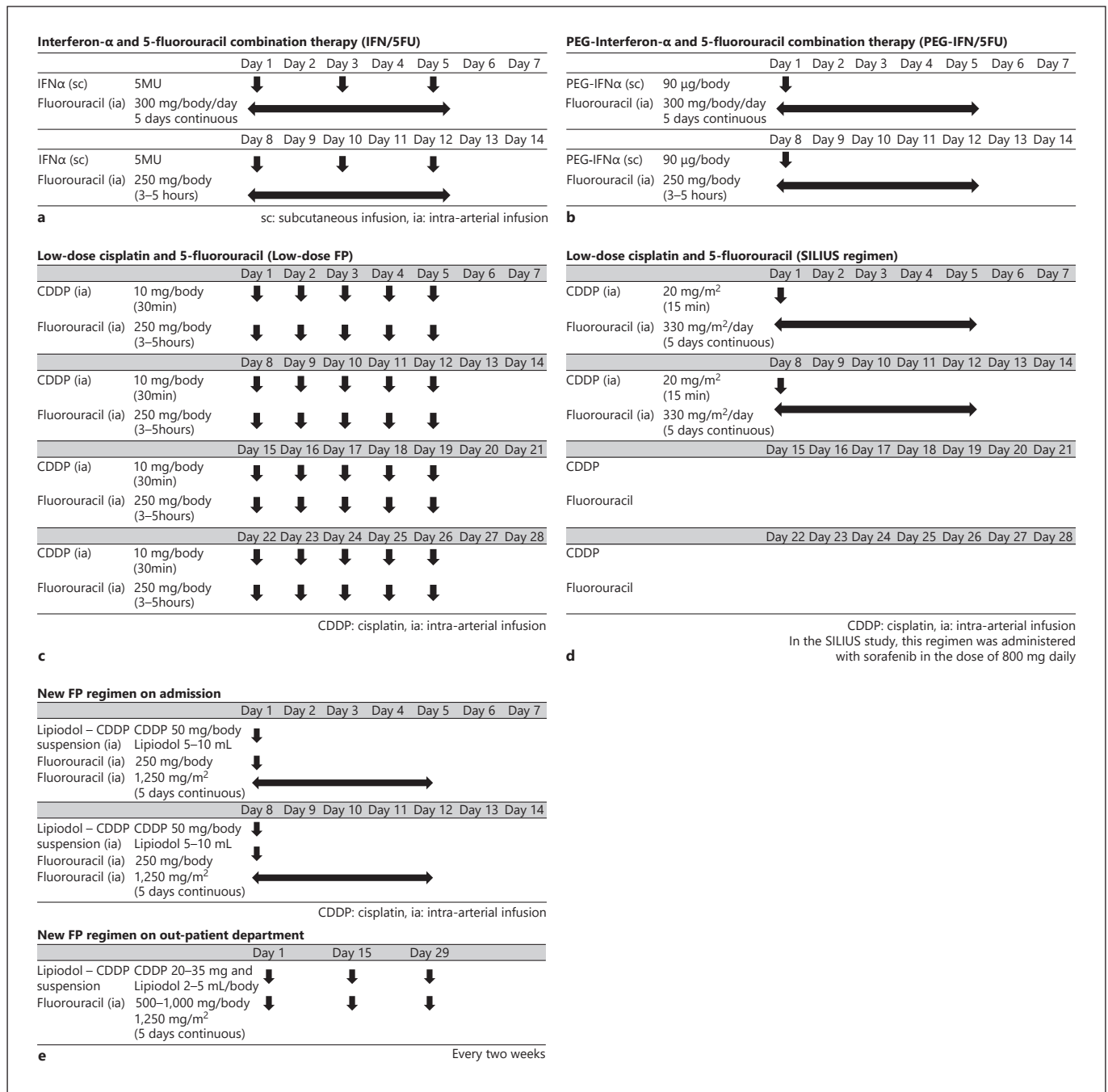


Fig. 2. **a** IFN/5FU. **b** PEG-IFN/5FU. **c** Low-dose cisplatin and 5-fluorouracil (Low-dose FP). **d** Low-dose cisplatin and 5-fluorouracil (SILIUS regimen). **e** New FP regimen. IFN/5FU, interferon-alpha and 5-fluorouracil combination therapy; PEG-IFN/5FU, PEG-interferon-alpha and 5-fluorouracil combination therapy.

11. Tumor markers

Some studies reported that alpha-fetoprotein and protein induced by vitamin K absence II (also known as des- γ -carboxyprothrombin) were related to OS [11, 12], but other studies found no association with OS [8, 9, 14, 15,

20]. In addition, alpha-fetoprotein and protein induced by vitamin K absence II were not found to be related to ORR [12, 14]. Therefore, it is not necessary to consider tumor marker levels for HAIC.

3. What Regimens Should Be Used in HAIC with a Port System for HCC?

Recommendation

Regimens that use FP are recommended (strong recommendation, level of evidence C).

Commentary

A wide variety of HAIC regimens have been reported, including the use of single drugs or combination regimens such as doxorubicin, epirubicin, mitomycin C, 5-fluorouracil, zinostatin stimalamer, cisplatin, miriplatin, and oxaliplatin. Generally, 5-fluorouracil-based regimens such as low-dose FP are used. Moreover, the effectiveness of the FOLFOX regimen using oxaliplatin, 5-fluorouracil, and leucovorin has recently been demonstrated. The currently used regimens for HCC are described in the following sections.

Combined Interferon and Intra-Arterial 5-Fluorouracil

This therapy consists of systemic interferon and intra-arterial 5-fluorouracil (Fig. 2a, b). Previous studies on combined interferon and intra-arterial 5-fluorouracil reported ORRs of 24.6%–73% and OS times of 6.9–14.7 months [35–44]. A retrospective study that compared combined interferon and intra-arterial 5-fluorouracil to a historical control observed a significant improvement in survival (1-year survival: 34% vs. 15%; 2-year survival: 18% vs. 5%, $p < 0.01$) [38].

A phase II trial on the effect of adding cisplatin to combined interferon and 5-fluorouracil observed a significant improvement in ORR and PFS versus interferon and 5-fluorouracil alone (ORR: 45.6% vs. 24.6%, $p = 0.030$; PFS: 6.5 months vs. 3.3 months, $p = 0.0048$) [41]. However, a phase II trial that compared combined interferon and 5-fluorouracil with the best salvage therapy (intra-arterial cisplatin or low-dose FP) did not produce a superior ORR (ORR: 26.7% vs. 25.8%) [42].

Low-Dose FP Therapy (Fig. 2c, d)

Low-dose FP therapy consists of low-dose cisplatin and continuous intra-arterial 5-fluorouracil. Previous studies on cisplatin (including high dose of cisplatin) plus 5-fluorouracil HAIC with a port system reported ORRs of 20%–71% and median OS times of 7.3–15.9 months [27, 44–53].

A propensity score analysis of patients with HCC registered to a nationwide database managed by the Liver Cancer Study Group of Japan found that low-dose FP

therapy was associated with a better prognosis than best supportive care (HR = 0.60, $p < 0.0001$), and low-dose FP therapy was also associated with a good prognosis in patients with four or more nodules or portal vein invasion [53]. A propensity score analysis comparing sorafenib and HAIC (mainly low-dose FP therapy) did not find significant differences in PFS or OS [19].

A retrospective study observed a better ORR with low-dose FP therapy than with sorafenib (30.9% vs. 4.8%) but no significant difference in OS [29]. However, after adjusting for portal vein invasion, OS was significantly longer in the low-dose FP group than in the sorafenib group (14 months vs. 7 months, $p = 0.005$).

A retrospective study that focused on portal vein invasion and refractoriness to TACE observed significantly better median OS with low-dose FP therapy than with sorafenib among non-TACE-refractory patients with portal vein invasion (13 months vs. 6 months). By contrast, among TACE-refractory patients without portal vein invasion, OS was significantly worse in the low-dose FP group than in the sorafenib group (8 months vs. 20 months) [29].

A retrospective trial comparing sorafenib and low-dose FP therapy in patients with portal vein invasion observed significantly better prognoses in the low-dose FP group than in the sorafenib group (OS: 309 days vs. 120 days) [27]. A phase III RCT to verify the additional effect of HAIC with a port system using low-dose FP (SILIUS trial) found a significant improvement in PFS (5.3 months vs. 3.5 months, $p = 0.004$) but not in OS (11.8 months vs. 11.5 months, $p = 0.955$). However, a sub-analysis suggested an additional effect of low-dose FP therapy among patients with main portal vein invasion (OS: 11.4 months vs. 6.5 months, $p = 0.050$) [25].

New FP Therapy (Fig. 2e)

The new FP therapy was conceived by Nagamatsu et al. [20]. This regimen consists of an arterial injection of powdered cisplatin with lipiodol followed by continuous intra-arterial 5-fluorouracil. Nakano and Niizeki conducted a nonrandomized prospective study of sorafenib and new FP therapy [54]. Twenty patients with HCC with no extrahepatic spread and macroscopic vascular invasion were treated with sorafenib, and 44 were treated with the new FP therapy. OS was significantly lower in the new FP group than in the sorafenib group (25 months vs. 13 months, $p = 0.0131$). The ORR of the new FP group was also significantly longer than that of the sorafenib group (71% vs. 10%).

Table 1. Results of HAIC with a port system for HCC

Regimen	<i>n</i>	ORR, %	TTP, months	PFS, months	OS, months	Author	Year	Ref. No
Combined systemic interferon and continuous intra-arterial 5-fluorouracil								
5FU+interferon- α	11	73	ND	ND	–	Sakon M	2002	[33]
5FU+interferon- α	55	43.6	ND	5.2	11.8	Ota H	2005	[35]
5FU+interferon- α	28	57.1	ND	ND	–	Enjoji M	2005	[34]
5FU+interferon- α	116	52	ND	ND	6.9	Obi S	2006	[36]
5FU+interferon- α	31	29	5.8	ND	7.5	Uka K	2007	[37]
5FU+interferon- α	102	39.2	ND	2	9	Nagano H	2011	[38]
5FU+interferon- α	57	24.6	ND	3.3	10.5	Yamashita T	2011	[39]
5FU+interferon- α	34	26.7	ND	3.5	8.4	Monden M	2012	[40]
5FU+Pegylated-interferon- α	55	44	ND	12.5	14.7	Wu J	2015	[41]
Low-dose FP therapy								
CDDP+5FU	31	71	ND	ND	–	Okuda K	1999	[43]
CDDP+5FU	48	48	ND	ND	10.2	Ando E	2002	[44]
CDDP+5FU	15	20	ND	ND	7.3	Yamasaki T	2005	[46]
CDDP+5FU	52	38.5	4.1	ND	15.9	Ueshima K	2010	[48]
CDDP+5FU	71	35	ND	ND	10.2	Niizeki T	2012	[50]
CDDP+5FU	476	40.5	ND	ND	13.9	Nouso K	2013	[51]
CDDP+5FU	32	31.3	ND	ND	309 days	Moriguchi M	2017	[25]
*CDDP+5FU	38	8	ND	ND	6	Cheong JY	2005	[45]
*CDDP+5FU	41	22	7	ND	12	Park JY	2007	[47]
*CDDP+5FU	97	27.8	ND	6	9.5	Kim BK	2011	[49]
New FP therapy								
5FU+CDDP+Lipiodol	51	86.3	–	8	33	Nagamatsu H	2010	[18]
5FU+CDDP+Lipiodol	52	75	–	8.6	27	Nagamatsu H	2016	[58]
5FU+CDDP+Lipiodol	44	71	–	9.5	30.4	Nakano M	2017	[52]
Combined sorafenib and low-dose FP therapy								
5FU+CDDP+Sorafenib	102	36	5.3	4.8	11.8	Kudo M	2018	[23]

ORR, objective response rate; TTP, time to response; PFS, progression-free survival; OS, overall survival; 5FU, 5-fluorouracil; CDDP, cisplatin. * High dose cisplatin+5FU.

Others

A phase I/II trial of combination 5-fluorouracil + mitoxantrone + cisplatin therapy for advanced HCC reported an ORR of 25%, PFS of 7.0 months, and OS of 11.3 months. Regarding grade 3/4 adverse events, 39% of patients exhibited neutropenia, 36% exhibited leukocytopenia, and 22% exhibited elevated AST [55].

A retrospective study that compared HAIC with a port system using FOLFOX to sorafenib found that HAIC significantly improved patient prognosis (PFS: 7.1 months vs. 3.3 months, $p < 0.001$; OS: 14.5 months vs. 7.0 months, $p < 0.001$) [56]. A phase II trial comparing HAIC using mFOLFOX to TACE observed significant improvements in the HAIC group (disease control rate: 83.8% vs. 52.5%, $p = 0.004$; PFS: 5.87 months vs. 3.6 months, $p = 0.015$) and significantly fewer grade 3/4 adverse events (12 vs. 27, $p = 0.007$) [57].

A phase II trial of combined sorafenib and HAIC using FOLFOX for patients with portal vein invasion reported an ORR of 40%, a disease control rate of 77.1%, a PFS of 6.7 months, and an OS of 13.2 months [58]. A phase III study found that sorafenib combined with HAIC using FOLFOX resulted in better OS than sorafenib alone in patients with portal vein invasion; however, femoral artery puncture and catheterization were performed every cycle, and a port system was not used in the trial [22].

4. What Are the Therapeutic Outcomes of HAIC with a Port System for HCC?

Statements

The therapeutic outcomes of HAIC with a port system vary depending on the regimen. Its local therapeutic effect is relatively high. With the commonly used low-dose

FP therapy, the response rates range from 24.5% to 71% [27, 45, 46, 48, 50, 52, 53]. However, HAIC with a port system has produced little evidence of a survival benefit.

Commentary

The regimens used in HAIC with a port system for HCC are (1) combined interferon and intra-arterial 5-fluorouracil, (2) low-dose FP therapy, (3) new-FP therapy, and (4) combined sorafenib and low-dose FP therapy. The results of each treatment are summarized in Table 1.

1. Combined systemic interferon and continuous intra-arterial 5-fluorouracil

Combination therapy with systemic interferon and intra-arterial 5-fluorouracil has been reported since 2002 [35–38, 40–43, 59], and the published studies examined 8–116 patients with portal vein invasion rates of 25%–100%. The ORRs ranged from 24.6% to 73%, and OS ranged from 6.9 to 14.7 months.

Obi et al. [38] reported the results of 116 patients with advanced HCC and portal vein invasion. The ORR was 52%, and OS was 6.9 months, which were better than the outcomes of untreated historical controls [38]. Yamashita et al. [41] reported an RCT comparing systemic interferon and continuous intra-arterial 5-fluorouracil with and without cisplatin in 114 patients with advanced HCC and a portal vein invasion rate of 27.5%. Systemic interferon and continuous intra-arterial FP produced a significantly higher ORR of 45.6% and OS of 17.6 months than systemic interferon and continuous intra-arterial 5-fluorouracil without cisplatin (ORR = 24.6%, OS = 10.5 months) [41].

2. Low-dose FP therapy

Low-dose FP therapy has been reported since 1999 [27, 45, 46, 48, 50, 52, 53], and studies have examined 31–114 patients with portal vein invasion rates of 26.4%–100%. The ORRs ranged 20%–71%, and OS ranged 7.3–15.9 months.

Niizeki et al. [52] conducted a retrospective analysis of 71 patients with advanced HCC and portal vein invasion and reported an ORR of 35% and an OS of 10.2 months. However, these studies were retrospective cohort studies as opposed to RCTs. The evidence level for this therapy is therefore not high [52].

3. New FP therapy

Three studies have reported new FP therapy [20, 54, 60]. Nakano et al. [54] conducted a nonrandomized prospective study that compared sorafenib with new FP therapy [54]. Twenty patients with HCC and vascular invasion but without distant metastasis received sorafenib, whereas 44 patients received new FP therapy. The median

OS was 13.2 months with sorafenib, versus 30.4 months with new FP therapy. The new FP therapy produced a significant improvement in OS ($p = 0.013$) and a significant antitumor effect. The ORR was 10% with sorafenib, vs. 71% with the new FP therapy.

4. Combined sorafenib and low-dose FP therapy

Kudo et al. [25] conducted an RCT comparing sorafenib alone with sorafenib plus HAIC with a port system using a low-dose FP regimen for the treatment of advanced HCC, mainly including patients with portal vein invasion. Sorafenib combined with low-dose FP therapy was administered to 102 patients, and sorafenib alone was administered to 103 patients. The ORR for the combination therapy was 36%, versus 18% for sorafenib alone, with the difference being significant. However, the OS rates in the combination and monotherapy groups were 11.8 and 11.5 months, respectively, with no significant difference observed.

A sub-analysis performed in this trial revealed that median OS in patients with main portal vein invasion was 11.4 months in those treated with sorafenib combined with low-dose FP therapy, versus 6.5 months (4.5–8.4) in those treated with sorafenib monotherapy (HR = 0.493, 95% CI = 0.240–1.014, $p = 0.050$). These results suggest that sorafenib combined with low-dose FP therapy might improve OS in patients with HCC and main portal vein invasion in comparison with sorafenib monotherapy.

5. What Therapies Can Be Combined with HAIC with a Port System for HCC?

Recommendations

Molecular targeted agents can be combined with HAIC with a port system (weak recommendation, level of evidence C).

Commentary

HAIC with a port system is widely used in patients with advanced HCC and bilobar multiple tumors or portal vein invasion. Molecular targeted therapy is also often selected in such cases [15–17, 31–33]. HAIC has a strong ability to shrink tumors; however, its survival benefit has not been confirmed. By contrast, sorafenib has been proven to extend survival, but its response rate is low. Kudo et al. [25] conducted a phase III trial comparing sorafenib monotherapy with sorafenib plus low-dose FP combination therapy to verify the effect of HAIC on survival. OS was 11.5 months (95% CI = 8.2–14.8) in the sorafenib monotherapy group, versus 11.8 months (95%

Table 2. Results of HAIC in combination with molecular targeted agent for HCC

Design	Phase	n	Arm	Regimen of HAIC	Port system	n	ORR, %	PFS, months	HR	p	OS, months	HR	p	Author	Year	Ref No.
RCT	III	125	Sorafenib+HAIC	FOLFOX	Without a port system	125	40.8	7.03	HR = 0.33	p < 0.001	13.37	HR = 0.35	p < 0.001	He M	2019	[20]
		122	Sorafenib			122	2.46	2.6			7.13					
Single arm	II	35	Sorafenib+HAIC	FOLFOX	Without a port system	35	40	6.7	-	-	13.2	-	-	He M	2018	[56]
RCT	III	102	Sorafenib+HAIC	Low dose FP	With a port system	102	36	4.8	HR = 0.753	p = 0.003	11.8	HR = 1.009	p = 0.955	Kudo M	2018	[23]
		103	Sorafenib			103	18	3.5			11.5					
RCT	II	66	Sorafenib+HAIC	CDDP	Without a port system	66	21.7	3.1	HR = 0.78	p = 0.09	10.6	HR = 0.60	p = 0.031	Ikeda M	2016	[59]
		42	Sorafenib			42	7.3	2.8			8.7					
Single arm	II	36	Lenvatinib+HAIC	CDDP	Without a port system	36	45.7	6.3	-	-	17.2	-	-	Ikeda M	2021	[60]

ORR, objective response rate; DCR, disease control rate; PFS, progression-free survival; OS, overall survival; HR, hazard ratio; RCT, randomized controlled trial; FOLFOX, oxaliplatin, fluorouracil, and leucovorin; CDDP, cisplatin; Low dose FP, low dose cisplatin and 5-fluorouracil; TTP, time to progression.

CI = 9.1–14.5) in the sorafenib plus low-dose FP combination therapy group (HR = 1.009, 95% CI = 0.743–1.371, $p = 0.955$). The safety of the combination therapy was confirmed. In a sub-analysis of patients with portal vein invasion, OS was 6.5 months (95% CI = 4.5–8.4) in the sorafenib monotherapy group, versus 11.4 months (95% CI = 7.0–15.9) in the sorafenib + low-dose FP combination therapy group, with the difference approaching significance (HR = 0.493, 95% CI = 0.240–1.014, $p = 0.050$), suggesting that HAIC has an additional effect on OS in patients with major portal vein invasion. Because conducting a large phase III trial on such a small patient group is unrealistic, it will be difficult to verify the additional effect of HAIC in patients with major portal vein invasion. Nevertheless, the use of this therapy appears to be feasible in clinical practice, and combination therapy with sorafenib and HAIC may be a safe and effective treatment option for patients with HCC and major portal vein invasion.

In addition, Ikeda et al. [61] reported that HAIC using cisplatin without a port system combined with sorafenib produced favorable OS versus sorafenib alone. The median survival times in the sorafenib alone and CDDP with sorafenib arms were 8.7 and 10.6 months, respectively (HR = 0.60, 95% CI = 0.38–0.96, $p = 0.031$) [61].

It was recently reported that HAIC using the FOLFOX regimen without a port system in combination with sorafenib produced a survival benefit in patients with HCC and major portal vein invasion [22, 57, 58]. Median OS was 13.37 months in the HAIC with sorafenib group versus 7.13 months in the sorafenib group (HR = 0.35, 95% CI = 0.26–0.48, $p < 0.001$). HAIC using the FOLFOX regimen combined with sorafenib was linked to longer PFS (7.03 months vs. 2.6 months) and a higher response rate (40.8% vs. 2.46%, $p < 0.001$) than sorafenib alone [22].

Ikeda et al. [62] presented at ESMO2021 that HAIC using cisplatin without a port system combined with lenvatinib produced a favorable objective response and OS. The ORRs according to modified RECIST and RECIST v1.1 were 64.7% and 45.7%, respectively. In addition, the median PFS and OS were 6.3 and 17.2 months, respectively [62]. Therefore, lenvatinib may be a good candidate drug for combination use with HAIC. The results of HAIC in combination with molecular targeted agents are summarized in Table 2.

All of the currently available regimens for HCC have anti-VEGF activity. Inhibition of VEGF induces vascular normalization and improves vascular permeability, thereby reducing intratumoral interstitial pressure, im-

proving drug delivery, and possibly enhancing the effect of HAIC [63, 64]. Therefore, all agents with anti-VEGF activity can be good candidates for combined use of HAIC. Conversely, the cytotoxic effect of HAIC can induce increased neoantigen production. Therefore, HAIC in combination with an immune checkpoint inhibitor-containing regimen such as atezolizumab plus bevacizumab might represent a promising treatment that activates the immune system.

6. What Are the Indications of HAIC with a Port System for Liver Metastases?

Recommendation

The indications for HAIC with a port system for the treatment of liver metastases are as follows: (1) the presence of liver metastases affecting the prognosis; (2) disease refractory to systemic chemotherapy (or not indicated); and (3) systemic chemotherapy not sufficiently effective against liver metastases that affect the prognosis (weak recommendation, level of evidence D).

Commentary

In HAIC with a port system, the presence or absence of extrahepatic lesions affects the prognosis [65–67]. HAIC may be performed when intrahepatic lesions are believed to have a greater impact on prognosis than extrahepatic lesions, when lesions are refractory to systemic chemotherapy, when lesions are not indicated for systemic chemotherapy, and when systemic chemotherapy is not sufficiently effective against a liver metastasis that affects the prognosis.

HAIC is sometimes considered in combination with systemic chemotherapy. HAIC was not found to be useful for preventing liver metastasis after resection, particularly in patients with colorectal cancer [68], whereas it was useful for reducing the risk of liver metastasis, although it did not improve OS [69]. HAIC has sometimes been performed in patients who were resistant to systemic chemotherapy, although its efficacy remains unclear [70–72].

7. What Regimens Should Be Used in HAIC with a Port System for Metastatic Liver Cancer?

Recommendations

For liver metastases of colorectal cancer, weekly high-dose 5-fluorouracil therapy or combined weekly high-dose 5-fluorouracil therapy and systemic irinotecan is

recommended (strong recommendation, level of evidence C). There are insufficient data to provide recommendations for other cancers (very weak recommendation, level of evidence D).

Commentary

Most studies on HAIC with a port system for liver metastases were concerned with liver metastases of primary colorectal cancer. However, some studies investigated liver metastases from primary gastric, breast, pancreatic, and biliary tract cancers (including gallbladder cancer and cancer of the ampulla of Vater).

Outside Japan, 5-fluorodeoxyuridine (FUdR) is often used for liver metastases of primary colorectal cancer [66, 73], although there are several reports from Japan on weekly high-dose 5-fluorouracil therapy or other 5-fluorouracil regimens. In a phase I/II trial of weekly high-dose 5-fluorouracil therapy, the ORR was 78%, and the median OS was 25.8 months (extrahepatic lesion no vs. yes: 25.9 months vs. 17.3 months) [65]. A retrospective study using the same regimen found similar results. A phase I/II trial of a combination regimen featuring weekly high-dose 5-fluorouracil and systemic irinotecan recorded an ORR of 72% and a median OS of 49.8 months [74]. Other studies used irinotecan or oxaliplatin as part of the arterial infusions [75, 76].

Regimens for liver metastases of gastric cancer are based on 5-fluorouracil (intra-arterial 5-fluorouracil only [77], 5-fluorouracil + epirubicin + mitomycin C [FEM regimen] [78], and 5-fluorouracil + cisplatin [FP therapy] [79]). The regimen for liver metastases of breast cancer is the FEM regimen [80]. Regimens for liver metastases of pancreatic cancer are intra-arterial 5-fluorouracil combined with systemic gemcitabine [81] and intra-arterial gemcitabine combined with systemic chemotherapy [82].

8. What Are the Therapeutic Outcomes of HAIC with a Port System for Liver Metastases?

Statements

The therapeutic outcomes of HAIC with a port system for liver metastases, which depend on the primary cancer or treatment regimen, are consistent local control effects in the liver with fewer systemic side effects than observed for systemic chemotherapy. If intrahepatic metastatic lesions affect the prognosis, HAIC with a port system may be considered.

Table 3. Results of HAIC with a port system for metastatic liver cancer

Primary lesion	Regimen	N	ORR, %	DCR, %	TTP, month	OS, month	Author	Year	Ref. No.
Colon cancer	5FU+LV ia	57	45	ND	9.2	18.7	Lorenz M	2000	[71]
	FUDR ia	54	43.2	ND	5.9	12.7			
	5-FU+LV iv	57	19.7	ND	6.6	17.6			
Colon cancer	FUDR ia	68	47	64	5.3	24.4	Kemeny N	1992	[97]
	5FU+LV iv	67	24	45	6.8	20.0			
Colon cancer	5FU ia	10 (Phase1)	80	100	ND	ND	Arai Y	1997	[63]
	5FU ia	32 (Phase2)	78	97	ND	25.8			
Colon cancer	5FU ia + CPT-11 iv	25	72	ND	ND	49.8	Arai Y	2012	[72]
Colon cancer	CPT-11 ia	12	33	58	ND	ND	Fiorentini G	2003	[73]
Colon cancer	L-OHP ia+FU/LV iv	28	64	75	27 (PFS)	27	Ducreux M	2005	[74]
Gastric cancer	5FU ia	18	83.3	ND	ND	19.2	Ojima H	2007	[75]
Gastric cancer	5FU+Epi-ADM+MMC ia	63	55.6	88.9	ND	10.5	Kumada T	1999	[76]
Gastric cancer	CDDP+5FU ia	7	–	ND	ND	16.5	Yamakado	2005	[77]
Breast cancer	5FU+ADM+MMC ia/5FU+Epi-ADM ia	56	81	ND	ND	12.5	Arai Y	1994	[78]
Pancreatic cancer	5FU ia + GEM iv	9	44.4	88.9	ND	14.1	Hashimoto A	2012	[79]
Pancreatic cancer	GEM ia + 5FU ia	5	60	100	ND	22.4	Tajima H	2013	[80]
	GEM ia +S1 po	2	50	50					

ORR, objective response rate; DCR, disease control rate; TTP, time to response; PFS, progression-free survival; OS, overall survival; ia, intra-arterial; iv, intravenous infusion; po, per os; ND, no data; 5FU, 5-fluorouracil; LV, leucovorin; FUDR, fluorodeoxyuridine; CPT-11, irinotecan; L-OHP, oxaliplatin; Epi-ADM, epirubicin; MMC, mitomycin-C; ADM, Adriamycin; GEM, gemcitabine; S-1, tegafur/gimeracil/oteracil potassium.

Commentary

The results of HAIC with a port system for metastatic liver cancer are summarized in Table 3. Kemeny et al. [66] conducted an RCT comparing HAIC with a port system using FUDR with systemic 5-fluorouracil + leucovorin for liver metastases of colorectal cancer. HAIC with a port system using FUDR produced better ORR (47% vs. 24%) and OS (24.4 months vs. 20 months) [66].

Phase II trials of weekly high-dose 5-fluorouracil therapy in Japan reported ORRs of 52%–83% and OS times of 18.6–26 months [65, 83, 84]. No global randomized trials have compared HAIC to FOLFOX and FOLFIRI, which are the current standard therapies. In Japan, phase I/II trials of the combination of HAIC plus intra-arterial 5-fluorouracil and systemic chemotherapy with intravenous irinotecan reported ORRs of 72%–86.4%, OS of 49.8 months, and PFS of 11.2 months [74, 85]. In a retrospective study, patients who were refractory to FOLFOX and FOLFIRI and who were administered intra-arterial 5-fluorouracil exhibited an ORR of 18.2%, an OS of 6.7 months, and a PFS of 2.8 months [71].

A phase II trial of intra-arterial FEM for hepatic metastases of gastric cancer reported an ORR of 55.6% and a median OS of 10.5 months [78]. A study that administered an FEM regimen to patients refractory to S1 reported an ORR of 42.9% and an OS of 12.7 months [86].

In a study of HAIC for hepatic metastases of breast cancer, an FEM regimen had an ORR of 81% [80]. A recent study on HAIC that used therapeutic regimens such as mitomycin/5-fluorouracil in patients that were refractory to systemic chemotherapy reported an ORR of 20% and an OS of 12 months [87].

Intra-arterial 5-fluorouracil had an ORR of 44.4% in patients with hepatic metastases of pancreatic cancer [81]. As described previously, the response rate varies depending on the type of carcinoma and regimen, but a high response rate is generally achieved. A limitation of HAIC with a port system is that the survival benefit has not been proven for patients who receive this treatment despite its high response rate. Liver metastasis should be regarded as a phenotype of systemic disease, and systemic chemotherapy should be given as the first-line treatment. However, if standard systemic chemotherapy is not indicated

or the patient is refractory, HAIC with a port system may be considered to avoid liver failure caused by tumor occupying the liver.

9. What Are the Complications and Treatments of HAIC with a Port System?

Statements

The complications of HAIC with a port system are categorized into those caused by the implanted catheter and port system and those caused by the injected drugs [88]. If complications caused by the implanted system are observed, removing and/or replacing the catheter system is necessary. If damage to the hepatic artery or gastrointestinal mucosa is caused by cytotoxic antitumor agents, cessation of the drug is necessary, and the port system should be checked immediately by angiography or CT angiography.

Commentary

Complications caused by the port system include migration of the indwelling catheter, catheter occlusion because of thrombus formation, catheter kinking, catheter-associated bloodstream infections, fibrin sheath formation, the port turning inside-out, and stenosis, occlusion, or pseudoaneurysm of the blood vessel in which the catheter is inserted [89–93]. In most cases, invasive treatments such as removing or replacing the catheter system are necessary.

Migration of the indwelling catheter may cause mucosal injury to the stomach and/or intestine when cytotoxic antitumor agents are injected. Slight migration of the catheter is acceptable if there is no drug spillage to organs outside the liver. If symptoms are caused by migration of the indwelling catheter, invasive treatments such as removing or replacing the catheter system are necessary.

Catheter occlusion attributable to thrombus formation or kinking may prevent the catheter from injecting the agent. When injection is difficult, the port system should be checked, and if occlusion or kinking of the catheter is suspected, the catheter should be replaced. Mixing heparin with an anticancer drug solution may prevent thrombotic obstruction of the catheter. Catheter-associated bloodstream infections may cause sepsis. Antibiotic therapy alone cannot cure this sepsis, and removal of the port system is needed.

Fibrin sheath formation may cause dysfunction of the port system or infection with the formation of biofilms.

Angiography via the port system will lead to arterial stenosis around the catheter side hole; however, conventional angiography may reveal that the hepatic artery is patent. Fibrin sheath formation can be resolved by replacing the catheter [91].

The implanted port is often turned inside-out. If this happens, needle puncture will be difficult, and repositioning is needed.

Stenosis and occlusion of the blood vessel in which the catheter is inserted may also cause dysfunction of the port system. For stenosis or occlusion of the common or proper hepatic artery, placing a metallic stent into the occluded artery may be useful.

Although relatively rare, complications such as cerebral infarctions have been reported when a catheter is placed via the subclavian artery. Ischemic change in the vertebral artery region can cause symptoms of cerebral infarction, but the symptoms are often not severe. In such cases, HAIC can be continued with conservative therapy including an antiplatelet agent.

Cytotoxic antitumor agents can cause vascular damage to the hepatic artery and damage the hepatic parenchyma or biliary system. Additionally, gastrointestinal ulcers can be caused by the leakage of cytotoxic antitumor agents into the digestive tract. The systemic circulation of cytotoxic antitumor agents can cause additional symptoms such as digestive organ symptoms and myelosuppression [65, 71, 80, 94–99]. Patients with a history of biliary reconstruction have a higher risk of hepatic abscess or biliary fistula.

Vascular damage to the hepatic artery caused by cytotoxic antitumor agents can be prevented by mixing hydrocortisone or other steroids with intra-arterial agents [100]. Symptoms of gastrointestinal ulcers caused by leakage into the digestive tract can be improved by histamine H2 receptor antagonists or proton pump inhibitors; however, if clear signs of blood flow to the digestive tract are observed on angiography via the port system, altering blood flow by coiling the artery causing the symptoms may be needed [101].

10. What Is the Appropriate Method for Implanting the Catheter and Port System?

Recommendation

The tip fixation method of percutaneous placement using an antithrombotic-coated catheter with a side hole is recommended (strong recommendation, level of evidence C).

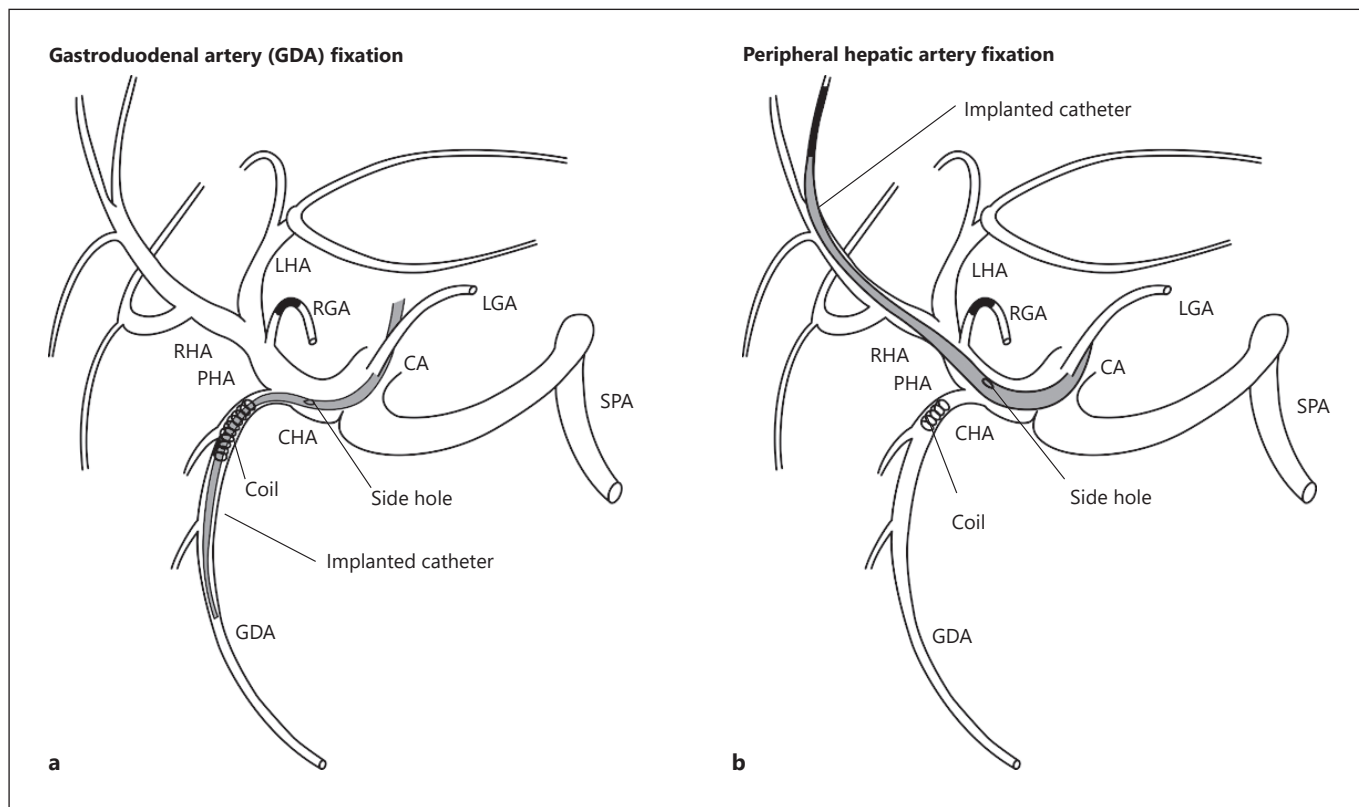


Fig. 3. a GDA fixation. **b** Peripheral hepatic artery fixation.

Commentary

Percutaneous placement of the port system using IVR technology is less invasive than surgical placement. The patency rate of the hepatic artery and the frequency of catheter migration following percutaneous placement compare favorably with those of surgical placement [102]. The tip fixation method for percutaneous placement using an antithrombotic-coated catheter with a side hole is recommended [90, 103].

An approach via the subclavian artery or inferior epigastric artery is preferred for inserting the catheter because these approaches do not pass through any joints and they are useful for preventing catheter migration [103]. The femoral artery approach is simple and widely used [104].

Gastroduodenal artery (GDA) fixation, in which the tip of the catheter is inserted into the GDA and is fixed using a metal coil, is the most commonly used method [90] (Fig. 3a). Peripheral hepatic artery fixation, in which the tip of the catheter is inserted into the peripheral branch of the hepatic artery and the side hole is placed in the proper hepatic artery, is another useful method [105] (Fig. 3b). In

every method, the right gastric artery and GDA should be embolized by a metallic coil to avoid mucosal injury or pancreatitis from the cytotoxic antitumor agents.

11. How Should an Implanted Catheter and Port System Be Managed after Placement?

Recommendation

1. When puncturing the port percutaneously, the skin should be disinfected using >0.5% chlorhexidine-alcohol (strong recommendation, level of evidence B).
2. A non-coring needle should be used to puncture the port (strong recommendation, level of evidence C).
3. After administering a drug via the implanted catheter and port system, heparin or a similar agent should be provided to prevent occlusion of the system (strong recommendation, level of evidence C).
4. Regular flow checks, i.e., CT angiography via the port system, are recommended to assess drug distribution from the port system (strong recommendation, level of evidence C).

Commentary

1. When puncturing the port subcutaneously, the skin should be disinfected using >0.5% chlorhexidine–alcohol.

Use >0.5% chlorhexidine–alcohol (used for skin disinfection in central vein catheters, in peripheral artery catheters, and when changing dressings) to disinfect the skin at the site of vascular access to the device. If chlorhexidine is not available, use povidone-iodine and 70% alcohol [106].

2. A non-coring needle should be used to puncture the port subcutaneously.

To prevent coring and hollowing out of the silicone septum, a non-coring needle (also called a Huber needle) should be used [107]. Package inserts for port systems state the number of punctures for which a non-coring needle can be used.

3. After administering a drug via the port system, flushing with an anticoagulant should be performed to prevent occlusion of the system.

Because the port system communicates directly with a blood vessel, the port and catheter can be filled with the anticoagulant heparin (heparin sodium 1,000 units/1 mL, depending on the volume of the port and catheter) [90], or the system can be flushed with a heparin saline solution [108] to prevent occlusion of the system due to backflow of blood.

4. Regular flow checks, i.e., angiography or CT angiography via the port system, are recommended to assess drug distribution from the implanted catheter and port system.

The distribution of drugs administered by the port system can be assessed by observing the distribution of a contrast agent injected via the port [109, 110]. The process of confirming the patency of the system and hepatic artery and checking the contrast agent distribution is called a flow check, and it is often conducted by combining digital subtraction angiography with CT angiography. If a flow check finds abnormal drug distribution inside or outside the liver, the blood flow should be adjusted as needed to make the drug distribution appropriate [103].

12. For Which Clinical Condition Should HAIC with a Port System Be Suspended or Discontinued?

Recommendations

HAIC with a port system should be suspended when there is disease progression or severe stenosis or occlu-

sion of the hepatic artery. HAIC can also be suspended after a complete response is maintained for a certain length of time (strong recommendation, level of evidence D).

Commentary

Generally, chemotherapy should be discontinued on disease progression. HAIC with a port system is often indicated for patients with relatively advanced primary or metastatic liver cancer. If other systemic chemotherapeutic options are available, a change of therapy should be considered even though mild disease progression may occur.

Therapy cannot be continued in patients with hepatic artery occlusion. Additionally, HAIC should be discontinued in patients with severe stenosis of the hepatic artery, which is likely to cause other complications [103, 111]. When image findings reveal a complete response, suspension of HAIC should be considered after continuing therapy for a certain period.

Long-term therapy has a risk of hepatic artery occlusion, whereas premature suspension of treatment can result in tumor regrowth [112]. In colorectal cancer, many patients who exhibit a complete response to systemic chemotherapy on imaging also exhibit viable cells on pathological analysis. Although it can be difficult to decide how long to continue therapy, there is a general consensus that therapy can be suspended after approximately 6 months of gradually extended treatment intervals [112, 113].

Conclusions

HAIC with a port system plays an important role in controlling intrahepatic tumors even though systemic chemotherapy remains the mainstream treatment for many cancers. In pathological conditions in which intrahepatic tumors affect the prognosis, HAIC with a port system has a weaker systemic effect from the viewpoint of side effects; it maximizes the local control effect, and it potentially improves the prognosis. This guideline summarizes the evidence and consensus for hepatic artery infusion reservoir therapy in Japan, and it is expected to contribute to the field of clinical practice.

Acknowledgments

We greatly acknowledge the support of Prof. Norihiro Kokudo (the former chairman of the Committee of Clinical Practice Guidelines for Hepatocellular Carcinoma) and Prof. Tetsuo Takehara (president of the JSH). We also thank Joe Barber Jr., PhD, from Edanz (<https://jp.edanz.com/ac>) for editing a draft of the manuscript.

Conflict of Interest Statement

Kazuomi Ueshima received honoraria and consulting or advisory fees from Bayer AG, Eisai Co. Ltd., Merck Sharp & Dohme, Eli Lilly and Company, Chugai Pharmaceutical Co., Ltd., Takeda Pharmaceutical Co., Ltd., Pfizer Inc., Otsuka Pharmaceutical Co., Ltd., Sumitomo Dainippon Pharma Co., Ltd., Taiho Pharmaceutical Co., Ltd., EA Pharma Co., Ltd., and Kowa Co., Ltd. and consulting or advisory fees from Eisai Co., Ltd., Eli Lilly and Company, Chugai Pharmaceutical Co., Ltd., Takeda Pharmaceutical Co., Ltd., and Pfizer Inc. Atsushi Komemushi, Takeshi Aramaki, Hideki Iwamoto, Shuntaro Obi, Yozo Sato, Toshihiro Tanaka, Kiyoshi Matsueda, Hiroya Saito, Miyuki Sone, and Yoshitaka Inaba have no relevant conflicts of interest to disclose. Michihisa Moriguchi received honoraria from Bayer, Eisai, Eli Lilly, and Chugai and consulting or advisory fees from Bayer, Eli Lilly, and Chugai. Takuji Yamagami received a research grant from Guerbet Japan, Nihon Medi-Physics, Eisai, Fujifilm Toyama Chemical Co. Ltd., GE Healthcare, Boston Scientific, and Fuji Pharma Co., Ltd. Masatoshi Kudo received honoraria and consulting or advisory fees from Bayer AG and Eisai Co., Ltd.; honoraria from Bayer AG, Bristol Myers Squibb, EA Pharma Co., Ltd., Eisai Co., Ltd., and Merck Sharp & Dohme; and research funding from Bayer AG, Daiichi

Sankyo Co., Ltd., Chugai Pharmaceutical Co., Ltd., Merck Sharp & Dohme, Otsuka Pharmaceutical Co., Ltd., Sumitomo Dainippon Pharma Co., Ltd., Ono Pharmaceutical Co., and Taiho Pharmaceutical. Yasuaki Arai received honoraria from Merit Medical Systems, Cosmotec, Fuji Pharma, Canon Medical Systems, Canon Medical Systems Asia Pte. Ltd., Canon Medical Systems Malaysia Sdn. Bhd., Sumitomo Bakelite, Boston Scientific Japan, Boston Scientific Corporation, Japan Lifeline, AstraZeneca plc, Guerbet Japan, Guerbet Asia Pacific, Kyorin Pharmaceutical, Daiichi Sankyo Co., Ltd., and Eisai Co., Ltd. Masatoshi Kudo is the Editor-in-Chief of *Liver Cancer*, and Kazuomi Ueshima is an Editorial Board Member of *Liver Cancer*.

Funding Sources

This article was funded with support from the Japanese Society of Implantable Port Assisted Treatment.

Author Contributions

Concepts: Kazuomi Ueshima and Atsushi Komemushi. Manuscript preparation: Kazuomi Ueshima, Atsushi Komemushi, Takeshi Aramaki, Hideki Iwamoto, Shuntaro Obi, Yozo Sato, Toshihiro Tanaka, Kiyoshi Matsueda, Michihisa Moriguchi, Hiroya Saito, Miyuki Sone, Takuji Yamagami, and Yoshitaka Inaba. Manuscript editing: Kazuomi Ueshima, Atsushi Komemushi, Takeshi Aramaki, Hideki Iwamoto, Shuntaro Obi, Yozo Sato, Toshihiro Tanaka, Kiyoshi Matsueda, Michihisa Moriguchi, Hiroya Saito, Miyuki Sone, Takuji Yamagami, and Yoshitaka Inaba. Manuscript review and approval: Masatoshi Kudo, Yasuaki Arai, and Yoshitaka Inaba.

References

- 1 Omata M, Cheng AL, Kokudo N, Kudo M, Lee JM, Jia J, et al. Asia-Pacific clinical practice guidelines on the management of hepatocellular carcinoma: a 2017 update. *Hepatol Int*. 2017 Jul;11(4):317–70.
- 2 European Association for the Study of the Liver. Electronic address eee, European Association for the Study of the L. EASL clinical practice guidelines: management of hepatocellular carcinoma. *J Hepatol*. 2018 Jul;69(1):182–236.
- 3 Heimbach JK, Kulik LM, Finn RS, Sirlin CB, Abecassis MM, Roberts LR, et al. AASLD guidelines for the treatment of hepatocellular carcinoma. *Hepatology*. 2018 Jan;67(1):358–80.
- 4 Kokudo N, Takemura N, Hasegawa K, Takayama T, Kubo S, Shimada M, et al. Clinical practice guidelines for hepatocellular carcinoma: the Japan Society of Hepatology 2017 (4th JSH-HCC guidelines) 2019 update. *Hepatol Res*. 2019 Oct;49(10):1109–13.
- 5 Shao YY, Wang SY, Lin SM, Diagnosis G; Systemic Therapy Group. Management consensus guideline for hepatocellular carcinoma: 2020 update on surveillance, diagnosis, and systemic treatment by the Taiwan Liver Cancer Association and the Gastroenterological Society of Taiwan. *J Formos Med Assoc*. 2021 Apr;120(4):1051–60.
- 6 Gordan JD, Kennedy EB, Abou-Alfa GK, Beg MS, Brower ST, Gade TP, et al. Systemic therapy for advanced hepatocellular carcinoma: ASCO guideline. *J Clin Oncol*. 2020 Dec 20;38(36):4317–45.
- 7 Vogel A, Martinelli E; ESMO Guidelines Committee. Updated treatment recommendations for hepatocellular carcinoma (HCC) from the ESMO clinical practice guidelines. *Ann Oncol*. 2021 Jun;32(6):801–5.
- 8 Fukui T, Yamaguchi N, Morizane T, Yoshida M, Kojimahara N. *Minds handbook for clinical practice guideline development*. 2014.
- 9 Guyatt GH, Oxman AD, Vist GE, Kunz R, Falck-Ytter Y, Alonso-Coello P, et al. GRADE: an emerging consensus on rating quality of evidence and strength of recommendations. *BMJ*. 2008 Apr 26;336(7650):924–6.
- 10 Arai Y. General concept of hepatic arterial infusion chemotherapy with implanted catheter system. In: *Japanese Society of Implantable Port Assisted Regional Treatment textbook of implantable port-assisted treatment*. Tokyo, Japan: Nankodo; 2003. p. 1–5.
- 11 Arai Y, Kamimura N, Suyama K. [A method to retain subcutaneously the catheter end connected to a new silicone reservoir in intraarterial infusion chemotherapy]. *Gan To Kagaku Ryoho*. 1982 Oct;9(10):1838–43.
- 12 Gyves J, Ensminger W, Niederhuber J, Liepman M, Cozzi E, Doan K, et al. Totally implanted system for intravenous chemotherapy in patients with cancer. *Am J Med*. 1982 Dec;73(6):841–5.
- 13 Niederhuber JE, Ensminger W, Gyves JW, Liepman M, Doan K, Cozzi E. Totally implanted venous and arterial access system to replace external catheters in cancer treatment. *Surgery*. 1982 Oct;92(4):706–12.
- 14 Itano O, Itano S, Nagamatsu H, Tsutsui R, Deguchi A, Inoue M, et al. Intermittent transcatheter therapy through a new indwelling catheter system for patients with hepatocellular carcinoma. *Jpn J Radiol*. 2014 Nov;32(11):670–5.

- 15 Finn RS, Qin S, Ikeda M, Galle PR, Ducreux M, Kim TY, et al. Atezolizumab plus Bevacizumab in Unresectable Hepatocellular Carcinoma. *N Engl J Med*. 2020 May 14;382(20):1894–905.
- 16 Llovet JM, Ricci S, Mazzaferro V, Hilgard P, Gane E, Blanc JF, et al. Sorafenib in advanced hepatocellular carcinoma. *N Engl J Med*. 2008 Jul 24;359(4):378–90.
- 17 Kudo M, Finn RS, Qin S, Han KH, Ikeda K, Piscaglia F, et al. Lenvatinib versus sorafenib in first-line treatment of patients with unresectable hepatocellular carcinoma: a randomised phase 3 non-inferiority trial. *Lancet*. 2018 Mar 24;391(10126):1163–73.
- 18 Llovet JM, Villanueva A, Marrero JA, Schwartz M, Meyer T, Galle PR, et al. Trial design and endpoints in hepatocellular carcinoma: AASLD consensus conference. *Hepatology*. 2021 Jan;73(Suppl 1):158–91.
- 19 Fukubayashi K, Tanaka M, Izumi K, Watanabe T, Fujie S, Kawasaki T, et al. Evaluation of sorafenib treatment and hepatic arterial infusion chemotherapy for advanced hepatocellular carcinoma: a comparative study using the propensity score matching method. *Cancer Med*. 2015 Aug;4(8):1214–23.
- 20 Nagamatsu H, Hiraki M, Mizukami N, Yoshida H, Iwamoto H, Sumie S, et al. Intra-arterial therapy with cisplatin suspension in lipiodol and 5-fluorouracil for hepatocellular carcinoma with portal vein tumour thrombosis. *Aliment Pharmacol Ther*. 2010 Aug;32(4):543–50.
- 21 Murakami E, Aikata H, Miyaki D, Nagaoki Y, Katamura Y, Kawaoka T, et al. Hepatic arterial infusion chemotherapy using 5-fluorouracil and systemic interferon- α for advanced hepatocellular carcinoma in combination with or without three-dimensional conformal radiotherapy to venous tumor thrombosis in hepatic vein or inferior vena. *Hepatol Res*. 2012;42(5):442–53.
- 22 He M, Li Q, Zou R, Shen J, Fang W, Tan G, et al. Sorafenib plus hepatic arterial infusion of oxaliplatin, fluorouracil, and leucovorin vs sorafenib alone for hepatocellular carcinoma with portal vein invasion: a randomized clinical trial. *JAMA Oncol*. 2019 Jul 1;5(7):953–60.
- 23 Song DS, Bae SH, Song MJ, Lee SW, Kim HY, Lee YJ, et al. Hepatic arterial infusion chemotherapy in hepatocellular carcinoma with portal vein tumor thrombosis. *World J Gastroenterol*. 2013 Aug 7;19(29):4679–88.
- 24 Miyaki D, Aikata H, Honda Y, Naeshiro N, Nakahara T, Tanaka M, et al. Hepatic arterial infusion chemotherapy for advanced hepatocellular carcinoma according to Child-Pugh classification. *J Gastroenterol Hepatol*. 2012 Dec;27(12):1850–7.
- 25 Kudo M, Ueshima K, Yokosuka O, Ogasawara S, Obi S, Izumi N, et al. Sorafenib plus low-dose cisplatin and fluorouracil hepatic arterial infusion chemotherapy versus sorafenib alone in patients with advanced hepatocellular carcinoma (SILIUS): a randomised, open label, phase 3 trial. *Lancet Gastroenterol Hepatol*. 2018 Jun;3(6):424–32.
- 26 Song DS, Song MJ, Bae SH, Chung WJ, Jang JY, Kim YS, et al. A comparative study between sorafenib and hepatic arterial infusion chemotherapy for advanced hepatocellular carcinoma with portal vein tumor thrombosis. *J Gastroenterol*. 2015 Apr;50(4):445–54.
- 27 Moriguchi M, Aramaki T, Nishiofuku H, Sato R, Asakura K, Yamaguchi K, et al. Sorafenib versus hepatic arterial infusion chemotherapy as initial treatment for hepatocellular carcinoma with advanced portal vein tumor thrombosis. *Liver Cancer*. 2017 Nov;6(4):275–86.
- 28 Hatooka M, Kawaoka T, Aikata H, Morio K, Kobayashi T, Hiramatsu A, et al. Comparison of outcome of hepatic arterial infusion chemotherapy and sorafenib in patients with hepatocellular carcinoma refractory to transcatheter arterial chemoembolization. *Anticancer Res*. 2016 Jul;36(7):3523–9.
- 29 Kodama K, Kawaoka T, Aikata H, Uchikawa S, Inagaki Y, Hatooka M, et al. Comparison of clinical outcome of hepatic arterial infusion chemotherapy and sorafenib for advanced hepatocellular carcinoma according to macrovascular invasion and transcatheter arterial chemoembolization refractory status. *J Gastroenterol Hepatol*. 2018 Oct;33(10):1780–6.
- 30 Terashima T, Yamashita T, Arai K, Kawaguchi K, Kitamura K, Yamashita T, et al. Response to chemotherapy improves hepatic reserve for patients with hepatocellular carcinoma and Child-Pugh B cirrhosis. *Cancer Sci*. 2016 Sep;107(9):1263–9.
- 31 Bruix J, Qin S, Merle P, Granito A, Huang YH, Bodoky G, et al. Regorafenib for patients with hepatocellular carcinoma who progressed on sorafenib treatment (RESORCE): a randomised, double-blind, placebo-controlled, phase 3 trial. *Lancet*. 2017 Jan 7;389(10064):56–66.
- 32 Abou-Alfa GK, Meyer T, Cheng AL, El-Khoueiry AB, Rimassa L, Ryoo BY, et al. Cabozantinib in patients with advanced and progressing hepatocellular carcinoma. *N Engl J Med*. 2018 Jul 5;379(1):54–63.
- 33 Zhu AX, Kang YK, Yen CJ, Finn RS, Galle PR, Llovet JM, et al. Ramucirumab after sorafenib in patients with advanced hepatocellular carcinoma and increased α -fetoprotein concentrations (REACH-2): a randomised, double-blind, placebo-controlled, phase 3 trial. *Lancet Oncol*. 2019 Feb;20(2):282–96.
- 34 Terashima T, Yamashita T, Arai K, Sunagozaka H, Kitahara M, Nakagawa H, et al. Feasibility and efficacy of hepatic arterial infusion chemotherapy for advanced hepatocellular carcinoma after sorafenib. *Hepatol Res*. 2014 Nov;44(12):1179–85.
- 35 Sakon M, Nagano H, Dono K, Nakamori S, Umeshita K, Yamada A, et al. Combined intra-arterial 5-fluorouracil and subcutaneous interferon-alpha therapy for advanced hepatocellular carcinoma with tumor thrombi in the major portal branches. *Cancer*. 2002 Jan 15;94(2):435–42.
- 36 Enjoji M, Morizono S, Kotoh K, Kohjima M, Miyagi Y, Yoshimoto T, et al. Re-evaluation of antitumor effects of combination chemotherapy with interferon-alpha and 5-fluorouracil for advanced hepatocellular carcinoma. *World J Gastroenterol*. 2005 Sep 28;11(36):5685–7.
- 37 Ota H, Nagano H, Sakon M, Eguchi H, Kondo M, Yamamoto T, et al. Treatment of hepatocellular carcinoma with major portal vein thrombosis by combined therapy with subcutaneous interferon-alpha and intra-arterial 5-fluorouracil; role of type 1 interferon receptor expression. *Br J Cancer*. 2005 Sep 5;93(5):557–64.
- 38 Obi S, Yoshida H, Toune R, Unuma T, Kanda M, Sato S, et al. Combination therapy of intra-arterial 5-fluorouracil and systemic interferon-alpha for advanced hepatocellular carcinoma with portal venous invasion. *Cancer*. 2006 May 1;106(9):1990–7.
- 39 Uka K, Aikata H, Takaki S, Miiki D, Jeong SC, Hiramatsu A, et al. Similar effects of recombinant interferon-alpha-2b and natural interferon-alpha when combined with intra-arterial 5-fluorouracil for the treatment of advanced hepatocellular carcinoma. *Liver Int*. 2007 Nov;27(9):1209–16.
- 40 Nagano H, Wada H, Kobayashi S, Marubashi S, Eguchi H, Tanemura M, et al. Long-term outcome of combined interferon-alpha and 5-fluorouracil treatment for advanced hepatocellular carcinoma with major portal vein thrombosis. *Oncology*. 2011;80(1–2):63–9.
- 41 Yamashita T, Arai K, Sunagozaka H, Ueda T, Terashima T, Yamashita T, et al. Randomized, phase II study comparing interferon combined with hepatic arterial infusion of fluorouracil plus cisplatin and fluorouracil alone in patients with advanced hepatocellular carcinoma. *Oncology*. 2011;81(5–6):281–90.
- 42 Monden M, Sakon M, Sakata Y, Ueda Y, Hashimura E, Group FR. 5-fluorouracil arterial infusion + interferon therapy for highly advanced hepatocellular carcinoma: a multicenter, randomized, phase II study. *Hepatol Res*. 2012 Feb;42(2):150–65.
- 43 Wu J, Huang WJ, Wang HY, Wang YF, Peng BG, Zhou Q. Arterial infusion of 5-fluorouracil combined with subcutaneous injection of pegylated interferon alpha-2b in treating unresectable hepatocellular carcinoma with portal vein tumor thrombus. *Med Oncol*. 2015 Mar;32(3):65.
- 44 Ikeda M, Morizane C, Ueno M, Okusaka T, Ishii H, Furuse J. Chemotherapy for hepatocellular carcinoma: current status and future perspectives. *Jpn J Clin Oncol*. 2018 Feb 1;48(2):103–14.
- 45 Okuda K, Tanaka M, Shibata J, Ando E, Ogata T, Kinoshita H, et al. Hepatic arterial infusion chemotherapy with continuous low dose administration of cisplatin and 5-fluorouracil for multiple recurrence of hepatocellular carcinoma after surgical treatment. *Oncol Rep*. 1999 May–Jun;6(3):587–91.
- 46 Ando E, Tanaka M, Yamashita F, Kuromatsu R, Yutani S, Fukumori K, et al. Hepatic arterial infusion chemotherapy for advanced hepatocellular carcinoma with portal vein tumor thrombosis: analysis of 48 cases. *Cancer*. 2002 Aug 1;95(3):588–95.

- 47 Cheong JY, Lee KM, Cho SW, Won JH, Kim JK, Wang HJ, et al. Survival benefits of intra-arterial infusion chemotherapy in patients with advanced hepatocellular carcinoma with portal vein tumor thrombosis. *Hepatol Res*. 2005 Jun; 32(2):127–33.
- 48 Yamasaki T, Kimura T, Kurokawa F, Aoyama K, Ishikawa T, Tajima K, et al. Prognostic factors in patients with advanced hepatocellular carcinoma receiving hepatic arterial infusion chemotherapy. *J Gastroenterol*. 2005 Jan;40(1): 70–8.
- 49 Park JY, Ahn SH, Yoon YJ, Kim JK, Lee HW, Lee DY, et al. Repetitive short-course hepatic arterial infusion chemotherapy with high-dose 5-fluorouracil and cisplatin in patients with advanced hepatocellular carcinoma. *Cancer*. 2007 Jul 1;110(1):129–37.
- 50 Ueshima K, Kudo M, Takita M, Nagai T, Tatsumi C, Ueda T, et al. Hepatic arterial infusion chemotherapy using low-dose 5-fluorouracil and cisplatin for advanced hepatocellular carcinoma. *Oncology*. 2010 Jul;78(Suppl 1):148–53.
- 51 Kim BK, Park JY, Choi HJ, Kim DY, Ahn SH, Kim JK, et al. Long-term clinical outcomes of hepatic arterial infusion chemotherapy with cisplatin with or without 5-fluorouracil in locally advanced hepatocellular carcinoma. *J Cancer Res Clin Oncol*. 2011 Apr;137(4):659–67.
- 52 Niizeki T, Sumie S, Torimura T, Kurogi J, Kuromatsu R, Iwamoto H, et al. Serum vascular endothelial growth factor as a predictor of response and survival in patients with advanced hepatocellular carcinoma undergoing hepatic arterial infusion chemotherapy. *J Gastroenterol*. 2012 Jun;47(6):686–95.
- 53 Nouse K, Miyahara K, Uchida D, Kuwaki K, Izumi N, Omata M, et al. Effect of hepatic arterial infusion chemotherapy of 5-fluorouracil and cisplatin for advanced hepatocellular carcinoma in the Nationwide Survey of Primary Liver Cancer in Japan. *Br J Cancer*. 2013 Oct 1; 109(7):1904–7.
- 54 Nakano M, Niizeki T, Nagamatsu H, Tanaka M, Kuromatsu R, Satani M, et al. Clinical effects and safety of intra-arterial infusion therapy of cisplatin suspension in lipiodol combined with 5-fluorouracil versus sorafenib, for advanced hepatocellular carcinoma with macroscopic vascular invasion without extra-hepatic spread: a prospective cohort study. *Mol Clin Oncol*. 2017 Dec;7(6):1013–20.
- 55 Ikeda M, Okusaka T, Sato Y, Furuse J, Mitsunaga S, Ueno H, et al. A Phase I/II trial of continuous hepatic intra-arterial infusion of 5-fluorouracil, mitoxantrone and cisplatin for advanced hepatocellular carcinoma. *Jpn J Clin Oncol*. 2017 Jun 1;47(6):512–9.
- 56 Lyu N, Kong Y, Mu L, Lin Y, Li J, Liu Y, et al. Hepatic arterial infusion of oxaliplatin plus fluorouracil/leucovorin vs. sorafenib for advanced hepatocellular carcinoma. *J Hepatol*. 2018 Jul; 69(1):60–9.
- 57 He MK, Le Y, Li QJ, Yu ZS, Li SH, Wei W, et al. Hepatic artery infusion chemotherapy using mFOLFOX versus transarterial chemoembolization for massive unresectable hepatocellular carcinoma: a prospective non-randomized study. *Chin J Cancer*. 2017 Oct 23;36(1):83.
- 58 He MK, Zou RH, Li QJ, Zhou ZG, Shen JX, Zhang YF, et al. Phase II study of sorafenib combined with concurrent hepatic arterial infusion of oxaliplatin, 5-fluorouracil and leucovorin for unresectable hepatocellular carcinoma with major portal vein thrombosis. *Cardiovasc Intervent Radiol*. 2018 May;41(5):734–43.
- 59 Kaneko S, Urabe T, Kobayashi K. Combination chemotherapy for advanced hepatocellular carcinoma complicated by major portal vein thrombosis. *Oncology*. 2002;62(Suppl 1):69–73.
- 60 Nagamatsu H, Sumie S, Niizeki T, Tajiri N, Iwamoto H, Aino H, et al. Hepatic arterial infusion chemoembolization therapy for advanced hepatocellular carcinoma: multicenter phase II study. *Cancer Chemother Pharmacol*. 2016 Feb;77(2):243–50.
- 61 Ikeda M, Shimizu S, Sato T, Morimoto M, Kojima Y, Inaba Y, et al. Sorafenib plus hepatic arterial infusion chemotherapy with cisplatin versus sorafenib for advanced hepatocellular carcinoma: randomized phase II trial. *Ann Oncol*. 2016 Nov;27(11):2090–6.
- 62 Ikeda M, Yamashita T, Ogasawara S, Kudo M, Inaba Y, Morimoto M, et al. Multicenter phase II trial of lenvatinib plus hepatic intra-arterial infusion chemotherapy with cisplatin for advanced hepatocellular carcinoma: LEOPARD. *Ann Oncol*. 2021;32(Suppl 5):S818–28.
- 63 Jain RK. Normalization of tumor vasculature: an emerging concept in antiangiogenic therapy. *Science*. 2005 Jan 7;307(5706):58–62.
- 64 Kano MR, Komuta Y, Iwata C, Oka M, Shirai YT, Morishita Y, et al. Comparison of the effects of the kinase inhibitors imatinib, sorafenib, and transforming growth factor-beta receptor inhibitor on extravasation of nanoparticles from neovasculature. *Cancer Sci*. 2009 Jan; 100(1):173–80.
- 65 Arai Y, Inaba Y, Takeuchi Y, Ariyoshi Y. Intermittent hepatic arterial infusion of high-dose 5FU on a weekly schedule for liver metastases from colorectal cancer. *Cancer Chemother Pharmacol*. 1997;40(6):526–30.
- 66 Kemeny NE, Niedzwiecki D, Hollis DR, Lenz HJ, Warren RS, Naughton MJ, et al. Hepatic arterial infusion versus systemic therapy for hepatic metastases from colorectal cancer: a randomized trial of efficacy, quality of life, and molecular markers (CALGB 9481). *J Clin Oncol*. 2006 Mar 20;24(9):1395–403.
- 67 Arai Y, Aoyama T, Inaba Y, Okabe H, Ihaya T, Kichikawa K, et al. Phase II study on hepatic arterial infusion chemotherapy using percutaneous catheter placement techniques for liver metastases from colorectal cancer (JFMC28 study). *Asia Pac J Clin Oncol*. 2015 Mar;11(1): 41–8.
- 68 Kusano M, Honda M, Okabayashi K, Akimaru K, Kino S, Tsuji Y, et al. Randomized controlled phase III study comparing hepatic arterial infusion with systemic chemotherapy after curative resection for liver metastasis of colorectal carcinoma: JFMC 29-0003. *J Cancer Res Ther*. 2017 Jan–Mar;13(1):84–90.
- 69 Sadahiro S, Suzuki T, Ishikawa K, Yasuda S, Tajima T, Makuuchi H, et al. Prophylactic hepatic arterial infusion chemotherapy for the prevention of liver metastasis in patients with colon carcinoma: a randomized control trial. *Cancer*. 2004 Feb 1;100(3):590–7.
- 70 Bouchahda M, Adam R, Giacchetti S, Castaing D, Brezault-Bonnet C, Hauteville D, et al. Rescue chemotherapy using multidrug chronomodulated hepatic arterial infusion for patients with heavily pretreated metastatic colorectal cancer. *Cancer*. 2009 Nov 1;115(21):4990–9.
- 71 Nishiofuku H, Tanaka T, Aramaki T, Boku N, Inaba Y, Sato Y, et al. Hepatic arterial infusion of 5-fluorouracil for patients with liver metastases from colorectal cancer refractory to standard systemic chemotherapy: a multicenter, retrospective analysis. *Clin Colorectal Cancer*. 2010 Dec;9(5):305–10.
- 72 Cercek A, Boucher TM, Gluskin JS, Aguilo A, Chou JF, Connell LC, et al. Response rates of hepatic arterial infusion pump therapy in patients with metastatic colorectal cancer liver metastases refractory to all standard chemotherapies. *J Surg Oncol*. 2016 Nov;114(6):655–63.
- 73 Lorenz M, Müller HH. Randomized, multicenter trial of fluorouracil plus leucovorin administered either via hepatic arterial or intravenous infusion versus fluorodeoxyuridine administered via hepatic arterial infusion in patients with nonresectable liver metastases from colorectal carcinoma. *J Clin Oncol*. 2000 Jan;18(2):243–54.
- 74 Arai Y, Ohtsu A, Sato Y, Aramaki T, Kato K, Hamada M, et al. Phase I/II study of radiologic hepatic arterial infusion of fluorouracil plus systemic irinotecan for unresectable hepatic metastases from colorectal cancer: Japan Clinical Oncology Group Trial 0208-DI. *J Vasc Interv Radiol*. 2012 Oct;23(10):1261–7.
- 75 Fiorentini G, Rossi S, Dentico P, Bernardeschi P, Calcinai A, Bonechi F, et al. Irinotecan hepatic arterial infusion chemotherapy for hepatic metastases from colorectal cancer: a phase II clinical study. *Tumori*. 2003 Jul–Aug;89(4): 382–4.
- 76 Ducreux M, Ychou M, Laplanche A, Gamelin E, Lasser P, Hussein F, et al. Hepatic arterial oxaliplatin infusion plus intravenous chemotherapy in colorectal cancer with inoperable hepatic metastases: a trial of the gastrointestinal group of the Federation Nationale des Centres de Lutte Contre le Cancer. *J Clin Oncol*. 2005 Aug 1;23(22):4881–7.
- 77 Ojima H, Ootake S, Yokobori T, Mochida Y, Hosouchi Y, Nishida Y, et al. Treatment of multiple liver metastasis from gastric carcinoma. *World J Surg Oncol*. 2007 Jun 21;5:70.
- 78 Kumada T, Arai Y, Itoh K, Takayasu Y, Nakamura K, Ariyoshi Y, et al. Phase II study of combined administration of 5-fluorouracil, epirubicin and mitomycin-C by hepatic artery infusion in patients with liver metastases of gastric cancer. *Oncology*. 1999 Oct;57(3):216–23.

- 79 Yamakado K, Nakatsuka A, Takaki H, Mori Y, Tonouchi H, Kusunoki M, et al. Prospective study of arterial infusion chemotherapy followed by radiofrequency ablation for the treatment of liver metastasis of gastric cancer. *J Vasc Interv Radiol*. 2005 Dec;16(12):1747–51.
- 80 Arai Y, Sone Y, Inaba Y, Ariyoshi Y, Kido C. Hepatic arterial infusion chemotherapy for liver metastases from breast cancer. *Cancer Chemother Pharmacol*. 1994;33(Suppl 1):S142–4.
- 81 Hashimoto A, Nishiofuku H, Tanaka T, Sho M, Anai H, Nakajima Y, et al. Safety and optimal management of hepatic arterial infusion chemotherapy after pancreatectomy for pancreaticobiliary cancer. *AJR Am J Roentgenol*. 2012 Apr;198(4):923–30.
- 82 Tajima H, Kitagawa H, Tsukada T, Okamoto K, Nakanuma SI, Sakai S, et al. Hepatic arterial infusion chemotherapy with gemcitabine and 5-fluorouracil or oral S-1 improves the prognosis of patients with postoperative liver metastases from pancreatic cancer. *Mol Clin Oncol*. 2013 Sep;1(5):869–74.
- 83 Kumada T. Weekly high-dose infusion of 5-fluorouracil for liver metastasis in colorectal cancer: multicenter study. *J Jpn Soc Cancer Ther*. 1993;28:1449.
- 84 Arai Y. Weekly 5 hour hepatic arterial infusion of high dose 5-FU for unresectable liver metastases from colorectal cancer in patients without extra-hepatic lesions. *Proc ASCO*. 1998;17:285a.
- 85 Yamaguchi T, Matsumoto H, Yasutome M, Mori T, Takahashi K. Phase I/II study of irinotecan, UFT and leucovorin with hepatic arterial infusion using 5-FU in colorectal cancer patients with unresectable liver metastases. *Cancer Chemother Pharmacol*. 2011 Mar;67(3):629–35.
- 86 Seki H, Ohi H, Ozaki T, Yabusaki H. Hepatic arterial infusion chemotherapy using fluorouracil, epirubicin, and mitomycin C for patients with liver metastases from gastric cancer after treatment failure of systemic S-1 plus cisplatin. *Acta Radiol*. 2016 Jul;57(7):781–8.
- 87 Tewes M, Peis MW, Bogner S, Theysohn JM, Reinboldt MP, Schuler M, et al. Hepatic arterial infusion chemotherapy for extensive liver metastases of breast cancer: efficacy, safety and prognostic parameters. *J Cancer Res Clin Oncol*. 2017 Oct;143(10):2131–41.
- 88 Arai Y. Techniques in various fields: hepatic arterial infusion chemotherapy. In: *Japanese Society of Implantable Port Assisted Regional Treatment textbook of implantable port-assisted treatment*. Tokyo: Nankodo; 2003. p. 60–72.
- 89 Imai R, Ito K, Ishigami N, Oba N, Nakajima N. Occlusion of the left superficial femoral artery during hepatic arterial infusion of chemotherapy for liver metastases from colon cancer 18 months after the implantation of a port system: a case report. *Jpn J Clin Oncol*. 2002 Feb;32(2):68–70.
- 90 Tanaka T, Arai Y, Inaba Y, Matsueda K, Aramaki T, Takeuchi Y, et al. Radiologic placement of side-hole catheter with tip fixation for hepatic arterial infusion chemotherapy. *J Vasc Interv Radiol*. 2003 Jan;14(1):63–8.
- 91 Yamagami T, Matsumoto T, Yoshimatsu R, Nishimura T. Dysfunction of a port-catheter system percutaneously implanted for hepatic arterial infusion chemotherapy due to a fibrin sheath. *Clin J Gastroenterol*. 2009 Feb;2(1):47–50.
- 92 Kobayashi Y, Hamano T, Kunii Y, Koide M. [A case of rupture of the right femoral artery pseudo aneurysm occurring in the site of a port for hepatic arterial infusion]. *Gan To Kagaku Ryo-ho*. 2010 Aug;37(8):1615–6.
- 93 Matsumoto T, Yamagami T, Yoshimatsu R, Morishita H, Kitamura N, Sato O, et al. Hepatic arterial infusion chemotherapy by the fixed-catheter-tip method: retrospective comparison of percutaneous left subclavian and femoral port-catheter system implantation. *AJR Am J Roentgenol*. 2014 Jan;202(1):211–5.
- 94 Kemeny MM, Battifora H, Blayney DW, Cecchi G, Goldberg DA, Leong LA, et al. Sclerosing cholangitis after continuous hepatic artery infusion of FUDR. *Ann Surg*. 1985 Aug;202(2):176–81.
- 95 Arai Y, Endo T, Sone Y, Tohyama N, Inaba Y, Kohno S, et al. Management of patients with unresectable liver metastases from colorectal and gastric cancer employing an implantable port system. *Cancer Chemother Pharmacol*. 1992;31(Suppl 1):S99–102.
- 96 Barnett KT, Malafa MP. Complications of hepatic artery infusion: a review of 4580 reported cases. *Int J Gastrointest Cancer*. 2001;30(3):147–60.
- 97 Ravizza D, Fazio N, Fiori G, Crosta C, Orsi F, Grasso R, et al. Iatrogenic gastroduodenal ulcers during hepatic intra-arterial chemotherapy. *Hepatogastroenterology*. 2003 Jan–Feb;50(49):49–53.
- 98 Kato Y, Matsubara K, Akiyama Y, Hattori H, Hirata A, Suzuki F, et al. Chemotherapy-induced sclerosing cholangitis as a rare indication for resection: report of a case. *Surg Today*. 2009;39(10):905–8.
- 99 Sato Y, Inaba Y, Ura T, Nishiofuku H, Yamaura H, Kato M, et al. Outcomes of a phase I/II trial of hepatic arterial infusion of oxaliplatin combined with intravenous 5-fluorouracil and l-leucovorin in patients with unresectable liver metastases from colorectal cancer after systemic chemotherapy failure. *J Gastrointest Cancer*. 2018 Jun;49(2):132–7.
- 100 Kemeny N, Seiter K, Niedzwiecki D, Chapman D, Sigurdson E, Cohen A, et al. A randomized trial of intrahepatic infusion of fluorodeoxyuridine with dexamethasone versus fluorodeoxyuridine alone in the treatment of metastatic colorectal cancer. *Cancer*. 1992 Jan 15;69(2):327–34.
- 101 Sato Y, Yoshitaka I, Hidekazu Y, Hayashi T, Shimamoto Y, Nishiofuku H, et al. Impact of microextrahepatic outflow arteries on WHF therapy. In: *29th Annual Meeting of Japanese Society of Implantable Port Assisted Regional Treatment*; 2005:62.
- 102 Arai Y. Basic techniques of hepatic arterial infusion chemotherapy in interventional radiology. *Rinsho Hoshasen*. 1993;38:1497–508.
- 103 Arai Y, Takeuchi Y, Inaba Y, Yamaura H, Sato Y, Aramaki T, et al. Percutaneous catheter placement for hepatic arterial infusion chemotherapy. *Tech Vasc Interv Radiol*. 2007 Mar;10(1):30–7.
- 104 Tajima T, Yoshimitsu K, Kuroiwa T, Ishibashi T, Irie H, Aibe H, et al. Percutaneous femoral catheter placement for long-term chemotherapy infusions: preliminary technical results. *AJR Am J Roentgenol*. 2005 Mar;184(3):906–14.
- 105 Irie T. Intraarterial chemotherapy of liver metastases: implantation of a microcatheter-port system with use of modified fixed catheter tip technique. *J Vasc Interv Radiol*. 2001 Oct;12(10):1215–8.
- 106 Miller DL, O'Grady NP; Society of Interventional Radiology. Guidelines for the prevention of intravascular catheter-related infections: recommendations relevant to interventional radiology for venous catheter placement and maintenance. *J Vasc Interv Radiol*. 2012 Aug;23(8):997–1007.
- 107 Inaba Y. Treatment and maintenance of implanted port system. In: *Japanese Society of Implantable Port Assisted Regional Treatment*. Tokyo: Nankodo; 2003. p. 87–90.
- 108 Deschamps F, Rao P, Teriithau C, Hakime A, Malka D, Boige V, et al. Percutaneous femoral implantation of an arterial port catheter for intraarterial chemotherapy: feasibility and predictive factors of long-term functionality. *J Vasc Interv Radiol*. 2010 Nov;21(11):1681–8.
- 109 Miller DL, Carrasquillo JA, Lutz RJ, Chang AE. Hepatic perfusion during hepatic artery infusion chemotherapy: evaluation with perfusion CT and perfusion scintigraphy. *J Comput Assist Tomogr*. 1989 Nov–Dec;13(6):958–64.
- 110 Seki H, Kimura M, Kamura T, Miura T, Yoshimura N, Sakai K. Hepatic perfusion abnormalities during treatment with hepatic arterial infusion chemotherapy: value of CT arteriography using an implantable port system. *J Comput Assist Tomogr*. 1996 May–Jun;20(3):343–8.
- 111 Seki H, Kimura M, Yoshimura N, Yamamoto S, Ozaki T, Sakai K. Hepatic arterial infusion chemotherapy using percutaneous catheter placement with an implantable port: assessment of factors affecting patency of the hepatic artery. *Clin Radiol*. 1999 Apr;54(4):221–7.
- 112 Arai Y. Criteria for the termination of treatment. In: *Japanese Society of Implantable Port Assisted Regional Treatment*. Tokyo: Nankodo; 2003. p. 175–7.
- 113 Benoist S, Brouquet A, Penna C, Julie C, El Hajjam M, Chagnon S, et al. Complete response of colorectal liver metastases after chemotherapy: does it mean cure? *J Clin Oncol*. 2006 Aug 20;24(24):3939–45.